



PATIENT

Peanutbutter
Rodriguez

SPECIES

Canine

BREED

Chihuahua

SEX

Female Intact

AGE

12 years

WEIGHT

5.5lbs

INTERPRETED BY

Maggie Machen Lamy,
DVM, DACVIM
(Cardiology)

IMAGING PERFORMED BY

G. Ferrer, DVM

HOSPITAL NAME

Pulse: Pet Ultrasound
Services

REFERRING VET

Dr. Irizarry

INVOICE

46347

DATE

1/8/26

PRESENTING CLINICAL SIGNS

History: Grade 5/6 heart murmur. Recently started to developed respiratory signs (tachypnea) while sleeping and coughing. On Furosemide 10mg/ml – 0.5ml SID, Vetmedin 0.25mg/kg PO q12h.

ECHOCARDIOGRAM FINDINGS

2D, m-mode and Doppler imaging are available. Diffuse thickening of mitral valve leaflets (anterior > posterior) with prolapse into the left atrial lumen. Severe eccentric mitral regurgitation with severe left atrial dilation. Significant LV dilation with hyperdynamic myocardial function. The tricuspid valve appears mildly thickened, with trace tricuspid regurgitation. Normal right heart. The pulmonic and aortic valves are normal in morphology and mobility. Normal pulmonic and aortic outflow velocities. No pulmonic or aortic insufficiency. No pericardial or pleural effusion noted. No cardiac tumors observed.

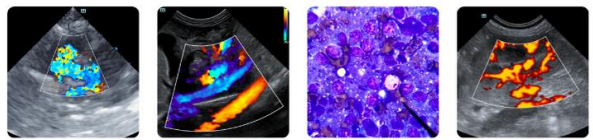
CARDIAC CHART

CANINE CARDIAC PARAMETERS	MR VMAX (m/s)	TR VMAX (m/s)	LA/AO (Boon method)	LA/AO (Heart Base; Swe)	FS (%)	EF (%)	EPSS (cm)
NORMAL PARAMETER	4.5-5.5	<2.7	1.3	<1.6	28-40	40-100	<0.6
PATIENT	5.2	NM	NM	2.0	60	92	0.2
CANINE CARDIAC PARAMETERS	HR (BPM)	AV VMAX (m/s)	PV MAX (m/s)	BODY WEIGHT (kg)	LA 2D short axis Base view (cm)	LVIDd Avg; 2D and m-mode short axis (cm)	LVIDs Avg; 2D and m-mode short axis (cm)
NORMAL PARAMETER	50-100	0.7-1.7	0.7-1.6	BELOW	BELOW	BELOW	BELOW
PATIENT	170	0.7	0.8	2.5	2.0	2.6	0.8
*Normal chamber parameters expressed as a mean value (SD)				3	1.27 (5.3)	2.46 (2.46)	1.36 (5.5)
BODY WEIGHT DEPENDENT PARAMETERS				5	1.40 (4.5)	2.74 (5.2)	1.60 (4.7)
*Note: All measurements based upon multi-modal images and methods. An average value is reported.				10	1.50 (3.8)	3.27 (3.5)	2.06 (3.1)
				15	1.83 (2.0)	3.71 (2.4)	2.43 (2.1)
				20	2.02 (1.9)	4.14 (2.2)	2.80 (2.0)
Adapted from June Boon, Veterinary Echocardiography, 1998				25	2.18 (2.4)	4.48 (2.9)	3.10 (2.5)
Rishniw M and Hollis NE, J Vet Intern Med 2000; 14:429-435				30	2.33 (3.3)	4.83 (3.9)	3.39 (3.4)
Hansson et al, Vet Rad and Ultrasound 2002				35	2.48 (4.3)	5.17 (5.0)	3.69 (4.5)
Bonagura et al. Echocardiography: principles of interpretation, Vet Clin North Am 15:1177, 1995				40	2.62 (5.2)	5.48 (6.1)	3.96 (5.4)
				50	2.88 (7.1)	6.07 (8.3)	4.46 (7.4)

INTERPRETATION OF THE FINDINGS & FURTHER RECOMMENDATIONS

The cause of the murmur is chronic degenerative valve disease causing severe mitral and trace tricuspid regurgitation. Severe left atrial enlargement indicates the risk for spontaneous congestive heart failure is elevated. No additional issues such as systolic dysfunction are identified.

The described cough is likely multi-factorial in origin, including a mechanical component due to cardiomegaly, possible concurrent airway disease and/or early CHF given the severity of disease. Screening chest radiographs are recommended with any change in symptom; however, given the symptoms and echo findings, full lifelong **cardiac support is recommended as below** including Lasix therapy. Depending on clinical response to the medications, cough suppression may also be useful. **Monitoring of sleeping breathing rates in the future will be paramount to determine the**



PATIENT

Peanutbutter
Rodriguez

SPECIES

Canine

BREED

Chihuahua

SEX

Female Intact

AGE

12 years

WEIGHT

5.5lbs

INTERPRETED BY

Maggie Machen Lamy,
DVM, DACVIM
(Cardiology)

IMAGING PERFORMED BY

G. Ferrer, DVM

HOSPITAL NAME

Pulse: Pet Ultrasound
Services

REFERRING VET

Dr. Irizarry

INVOICE

46347

DATE

1/8/26

origin of any future cough. The average survival of canine patients with active pulmonary edema is 8-9 months on medications; however, they generally are able to maintain a good quality of life for that period. Patient will always be at risk for recurrent CHF, development of arrhythmias/LA tear, syncope and/or sudden death in the future. Monitoring of renal values is recommended lifelong.

Omega fatty acid supplementation and mild salt restriction may also be of some long-term benefit. Monitor for development of a worsening cough, labored breathing, exercise intolerance or collapse episodes.

Elective anesthesia is not advised, as there is high risk for complication. Risk: benefit ratio should be considered. Consider consultation with and/or referral to a facility with an anesthesiologist. Should you elect to proceed, cardiac protective drug choices (opioid/benzodiazepine premedication, propofol or alfaxalone induction, iso or sevoflurane gas) are recommended. Pre-oxygenate for 5-10 minutes prior to induction and recover in O2 cage. Monitor for arrhythmias, hypotension, and hypoxia both intra and post-operatively and intervene as necessary. Moderate IV fluid restriction is recommended to avoid fluid overload, while considering comorbidities, hydration status, BP, etc. Avoid heart rate stimulating drugs such as atropine unless clinically indicated.

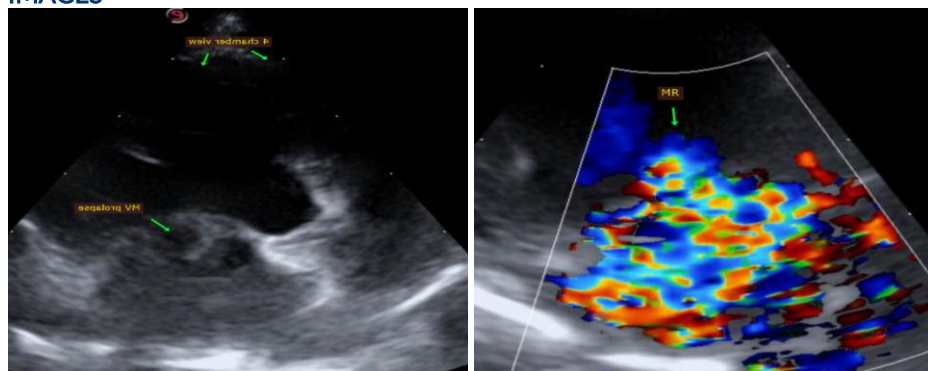
PLAN

Screening BP and CXR recommended. Continue Pimobendan 0.3mg/kg PO q12h. Continue Lasix to BID dosing. Administer Spironolactone 1-2mg/kg PO q12h. Consider hydrocodone with homatropine (0.2-0.4mg/kg PO up to q4-6 hours PRN) if cough persists despite normal SRRs.

A renal panel and BP are recommended in 10-14 days, then every 3-4 months on diuretics to ensure tolerance of medications. If doing well at that time and BP >130mmHg, institute ACEI 0.5mg/kg PO q12h.

A recheck echocardiogram is recommended in 6 months to screen for progression, sooner if clinical signs arise/persist.

IMAGES



The information and recommendations provided are based on the images presented by the referring veterinarian. No evaluation can be communicated regarding pathology that was not visible in the image/video clips provided.



PATIENT

Peanutbutter
Rodriguez

SPECIES

Canine

BREED

Chihuahua

SEX

Female Intact

AGE

12 years

WEIGHT

5.5lbs

INTERPRETED BY

Maggie Machen Lamy,
DVM, DACVIM
(Cardiology)

IMAGING PERFORMED BY

G. Ferrer, DVM

HOSPITAL NAME

Pulse: Pet Ultrasound
Services

REFERRING VET

Dr. Irizarry

INVOICE

46347

DATE

1/8/26

Thank you for this referral. This report was generated using transcription software, and minor dictation errors may be present. If the clinical or image interpretation does not parallel your findings or if I can be of any further assistance, please contact me.

Maggie Machen Lamy, DVM
Diplomate of the American College of Veterinary Internal Medicine (Cardiology)
info@sonopath.com